

SETTLEMENT DEMAND

**PRIVILEGED/CONFIDENTIAL COMMUNICATION
SOLELY FOR USE IN SETTLEMENT NEGOTIATIONS**

DATE: _____

Addressee:

Our Client : Johnny Doe
Your Client : Charlie Charlie
Claim Number :
Date of Loss : August 30, 20xx

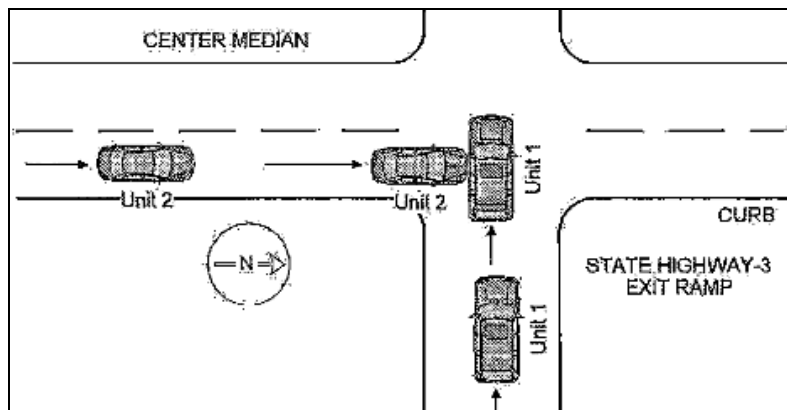
Dear _____,

This office represents Johnny Doe concerning the injuries he sustained in an August 30, 20xx, motor vehicle collision that resulted from the negligence of your client Charlie Charlie.

FACTS AND LIABILITY

On August 30, 20xx, Mr. Johnny Doe was the properly restrained driver of a 20xx Silver Dodge Dart (Unit 2), traveling northbound on State Highway-1 South, Pontotoc County, Oklahoma. Your client, Mr. Charlie Charlie, was driving a 20xx Silver Nissan Rogue. Mr. Charlie was stopped at a westbound stop sign from the Richardson Loop Exit Ramp and State Highway-1 South. Mr. Charlie negligently ran the stop sign and floated through the intersection in front of Mr. Doe's Dodge Dart. This reckless maneuver by Mr. Charlie resulted in a T-bone collision of the two vehicles.

The Traffic Collision Report prepared by Oklahoma Highway Patrol (**Exhibit 1**) determined that your client, Mr. Charlie, contributed to the collision by failing to yield from the stop sign.



PROPERTY DAMAGE

As a result of the August 30, 20xx collision, Mr. Doe's 20xx Silver Dodge Dart sustained significant functional damages in the amount of \$_____.

SUMMARY OF PHYSICAL INJURIES

As a result of the collision, Mr. Doe, a 60-year-old male, sustained the following injuries:

- Head/Brain – Cephalgia; Post-concussion syndrome; Acute non-intractable headache
- Cervical Spine – Disc bulges/protrusions at the C3-C4, C4-C5, C5-C6, C6-C7, and C7-T1 levels; Disc flattening at the C5-C6 and C6-C7 levels; Cord compression; Stenosis; Herniated nucleus pulposus; Strain/sprain; Trigger Points; Radiculopathy; Cervicalgia
- Thoracic Spine – Strain/sprain; Trigger Points
- Lumbar Spine – Strain/sprain; Trigger Points; Radiculopathy
- Bilateral Trapezius - Spasms
- SI joints – Sprain
- Chest pain

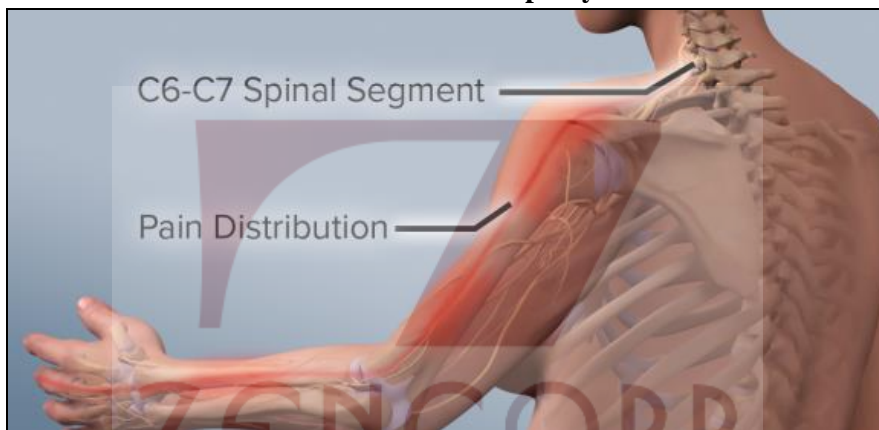
TREATMENT OF INJURIES

On September 2, 20xx, Mr. Doe presented to the Emergency Department of ABC Hospital (**Exhibit 2**), where Dallas Wright, D.O., examined him for complaints of generalized headaches that were pretty much constant, waxing, and waning. He quantified the severity of his pain as 5/10 on the pain scale. CT of his head revealed marked areas of decreased attenuation in his periventricular white matter and subcortical white matter. His Physician diagnosed him with acute nonintractable headache. He was administered Compazine, Benadryl, Toradol, and Decadron injections in the ED. He was recommended to obtain an MRI of his brain to evaluate his symptoms further. He was advised to follow up with his Primary Care Physician for complete care and evaluation.

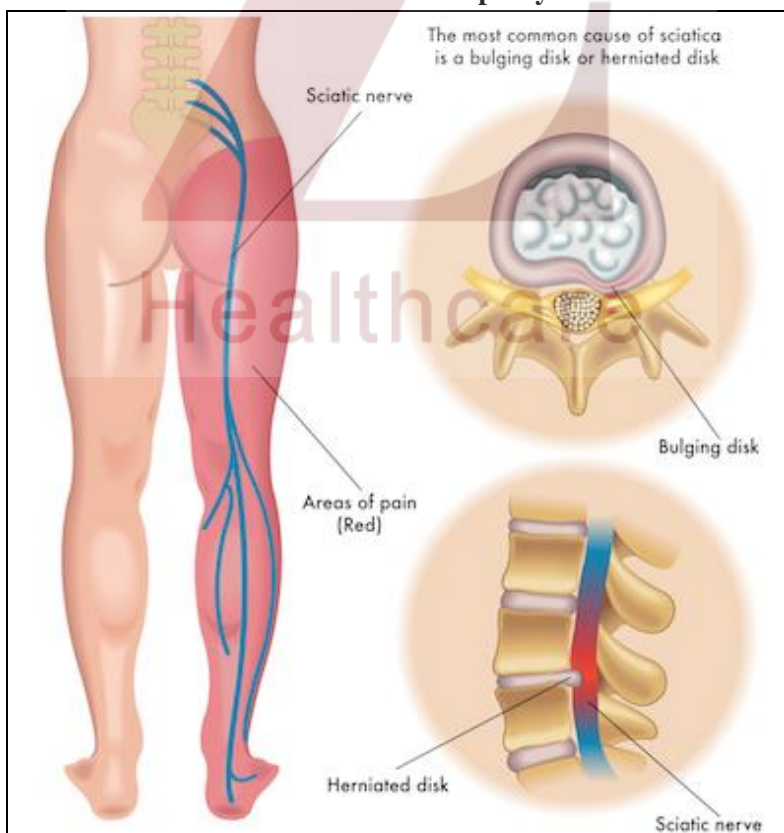
On September 24, 20xx, Mr. Doe presented to Steve Randall, M.D., at The ABC Clinic (**Exhibit 3**) for complaints of soreness and tightness in his neck. He also complained of sharp pain in his upper back that radiated down his right arm, along with numbness in his right hand. He had soreness and sharp pain in his trapezius and sharp, shooting pain in his head and low back. He felt fragile. He also reported headaches and ringing in his ears, along with dizziness and blurred vision. The findings on his physical examination revealed palpable tenderness and trigger points in his neck, trapezius, and entire back muscles. The severe pain restricted his cervical, thoracic, and lumbar range of motion. He had decreased sensation to monofilament testing in his upper and lower extremities. He also had palpable tenderness in his sacroiliac (SI) joints with diminished joint play and palpable muscle spasm in his trapezius musculature. X-ray of his cervical and lumbar spine revealed moderate left spinous process rotation at the L1 through L2 levels, C2 through C3 levels, and on his right side at the C5 and L4 levels. The radiology report also revealed moderate hypolordosis of his cervical and lumbar spine. After a thorough examination of the injured areas, his Physician determined that his symptoms were causally

related to the motor vehicle collision. His Physician diagnosed him with sprain/strain of his cervical, lumbar, and thoracic spine with trigger points, cervical and lumbar radiculopathy, spasms in his trapezius, cephalgia/post-concussion syndrome, and sprain of his sacroiliac joints. He was referred to a facility in Ada, Oklahoma, to undergo a course of rehabilitative therapy two times per week to reduce his pain and restore his range of motion, strength, and endurance. He was advised to follow up in approximately two to three weeks to monitor his progress.

Cervical Radiculopathy

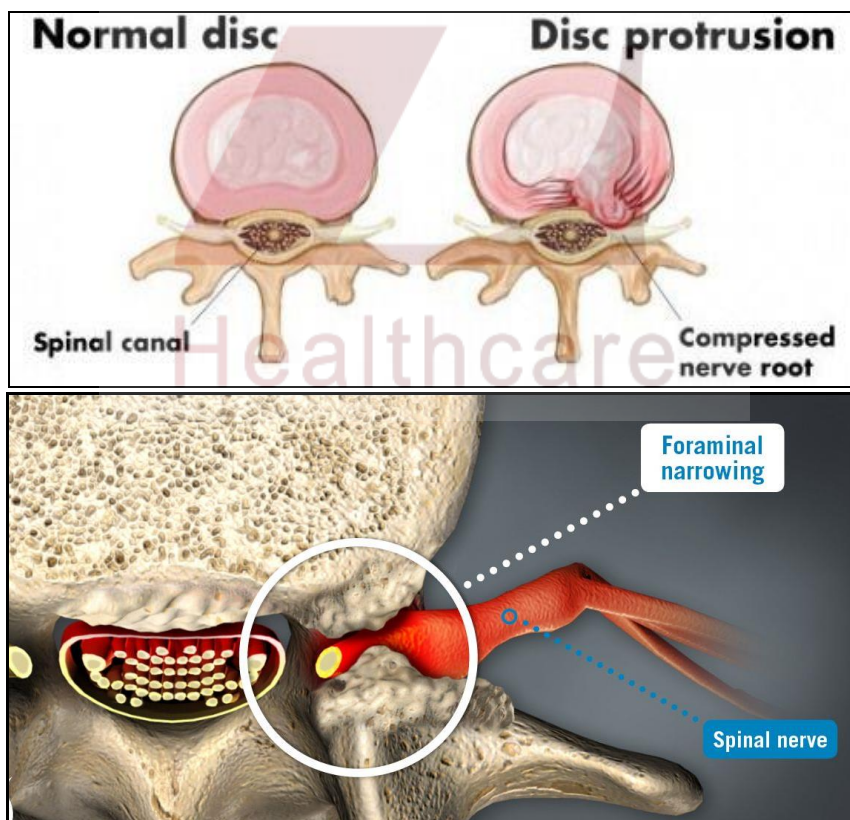


Lumbar Radiculopathy



On September 29, 20xx, Mr. Doe was seen and evaluated by Doyle Walker, PT at SS Physical Therapy (**Exhibit 4**), for complaints of pain in his neck and back. He quantified the severity of his pain as 8/10 on the pain scale. He scored 50 on Neck Disability Index that indicated 50% impairment, and 44 on Oswestry Disability Index that indicated 44% impairment. The findings on his physical examination revealed palpable pain and tenderness in his neck and back muscles. He had decreased thoracic kyphosis and cervical and lumbar lordosis on postural analysis. He also had decreased strength in his upper and lower extremities. His Physician diagnosed him with cervicgia and low back pain. He was recommended to attend rehabilitative therapy for two visits a week with an expected duration of two weeks. His treatment consisted of electrical stimulation, hot/cold pack therapy, neuromuscular re-education, self-care/home management training, therapeutic activities, and therapeutic procedures.

On October 23, 20xx, an MRI of Mr. Doe's cervical spine and brain was obtained by Jeffrey L. Watts, M.D., at ABC Diagnostic Imaging (**Exhibit 5**). MRI of his cervical spine revealed posterior disc protrusion at the C3-C4 and C7-T1 levels, disc bulge at the C4-C5 and C6-C7 levels, significant disc pathology centered right of midline and foraminal endplate spurring at the C5-C6 level, along with foraminal narrowing at the C2-C3, C3-C4, C5-C6, C6-C7, and C7-T1 levels that had compromised the exiting C3, C4, C5, C6, C7, and C8 nerves. MRI of his brain revealed moderate, prominent periventricular and deep white matter disease in both hemispheres, likely microvascular, demyelination, and global atrophy.



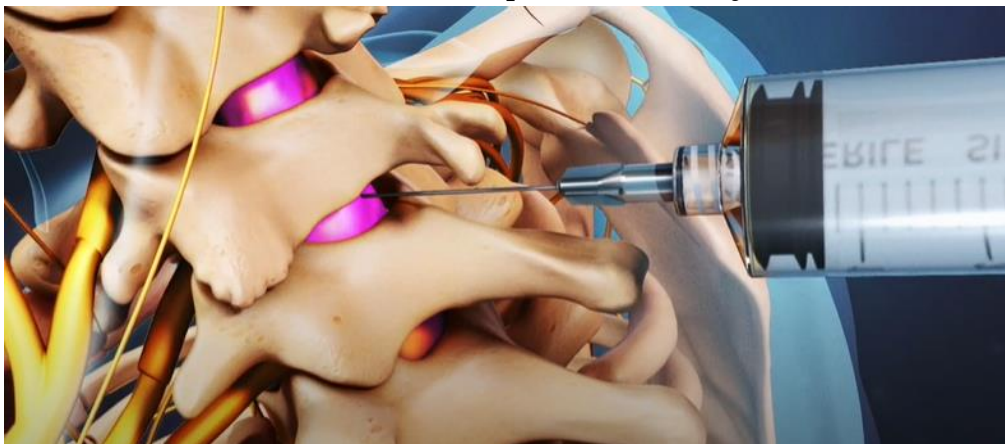On November 09, 20xx, Mr. Doe presented to the Emergency Department of Heart Hospital South (**Exhibit 6**), where Lyndon D. Eldridge, D.O., examined him for complaints of pain in his scapular area, chest, and neck. He had shortness of breath at rest associated with this. He also had intermittent headaches. He had a history of coronary artery disease with CABG several years ago. He was tachycardic and uncomfortable. X-ray of his chest and EKG were obtained and reviewed. His Physician diagnosed him with chest pain. He was recommended to continue his home medications as prescribed. He was advised to follow up with his Primary Care Physician for further evaluation and treatment.

On November 13, 20xx, Mr. Doe returned to Steve Randall, M.D., at The ABC Clinic to re-evaluate his complaints. He had frequent pain and stiffness in his neck, along with numbness and tingling in his right upper extremity. He continued to have frequent pain in his low back with radicular symptoms. He also had persistent headaches and pain, and stiffness in his trapezius. He was additionally diagnosed with disc bulges/protrusions at the C3-C4, C4-C5, C5-C6, C6-C7, and C7-T1 levels, disc flattening at the C5-C6 and C6-C7 levels, cervical cord compression, and cervical stenosis. Due to abnormal findings on his cervical MRI and multi-level disc involvement, he was recommended to undergo nerve conduction studies of his cervical plexus to determine the level of disc involvement causing his radicular symptoms. Dr. Randall also recommended that he undergo a series of epidural steroid injections to his cervical spine following the nerve conduction study that would approximately cost \$12,000.00 to \$16,000.00. Due to his persistent headaches and the severe findings on his MRI, his Physician recommended an evaluation with Dr. Gabriel Pitman, a neurologist. He was advised to continue attending physical therapy sessions at SS Physical Therapy two times per week while awaiting authorization for the referrals.

On December 01, 20xx, Mr. Doe had an electrodiagnostic study performed by RD Schubert, DC, at MM Diagnostic (**Exhibit 7**) for his presumptive diagnosis of sensory cervical plexus disorder. The study revealed a severe elevation of action potential threshold for the A-delta pain fibers of the C6 dermatome on his right side. The study raised suspicion for a compressive or inflammatory lesion at the C5-C6 spinal level.

On December 03, 20xx, Mr. Doe received a cervical interlaminar epidural steroid injection at the C7-T1 level. Steve E. Randall, M.D., performed the procedure at IV Spine Services (**Exhibit 8**).

Cervical Interlaminar Epidural Steroid Injection



On December 21, 20xx, Mr. Doe visited Steve Randall, M.D., at The ABC Clinic to re-evaluate his complaints. He had only minimal relief after receiving the epidural steroid injection. The numbness and tingling in his arms and hands had returned. He had frequent stiffness in his upper back. He also had frequent pain and stiffness in his low back and trapezius. He still had palpable tenderness and trigger points in his neck and trapezius muscles. He also had persistent spasms in his trapezius. Dr. Randall recommended that he undergo a second epidural steroid injection to his cervical spine at an approximate cost of \$4,000.00 to \$5,000.00. He was advised to continue attending physical therapy sessions while awaiting authorization for the injections. He was instructed to follow up in two to three weeks to reassess his progress.

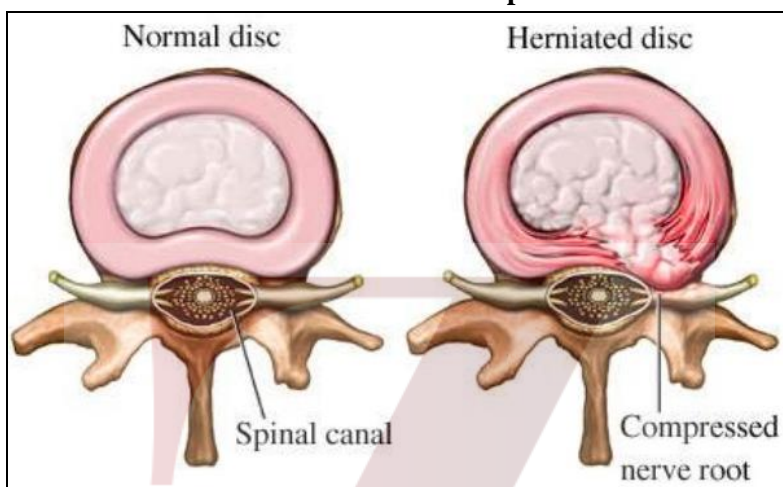
From October 08, 20xx, through January 07, 2021, Mr. Doe attended an extensive physical therapy session at SS Physical Therapy under the care of Doyle Walker, PT, for the complaints of persistent pain in his neck and low back. On October 13, 20xx, he complained of pain in the back of the right side of his head while waking up in the mornings. On October 15, 20xx, he had increased pain towards the right side of his neck that radiated down his arm and into the anterior chest. He felt like his neck was numb. He rated the pain severity as 7/10 on the pain scale. On October 22, 20xx, he had a re-evaluation of his complaints. He continued to complain of increased pain in his neck and back while attempting to move. His Neck Disability Index score was 54, and his Oswestry Disability index score was 50. Therefore, the frequency of his visit was increased to 15 visits with an expected duration of 90 days. On October 19, 20xx, he continued to complain of neck stiffness and muscular tightness. On November 24, 20xx, he reported soreness in his right shoulder. On December 16, 20xx, he still complained of numbness and tingling in his hands, despite undergoing epidural steroid injection. On December 30, 20xx, his Chiropractor observed that his response to treatment was slow. His treatment consisted of electrical stimulation, hot/cold pack therapy, manual therapy, neuromuscular re-education, therapeutic activities, and therapeutic procedures.

On January 14, 2021, Mr. Doe presented to Doyle Walker, PT, at SS Physical Therapy for his final physical therapy evaluation. He had temporary relief after each therapy that lasted only for about three hours. He had persistent pain and tenderness in his neck and low back. His Neck Disability Index score was 50, and his Oswestry Disability Index score was 60. He also had decreased function and strength. Despite attending several therapy sessions, his pain remained unabated. His therapist determined that he might require further surgery in the future. His treatment consisted of electrical stimulation, hot/cold pack therapy, manual therapy, neuromuscular re-education, therapeutic activities, and therapeutic procedures.

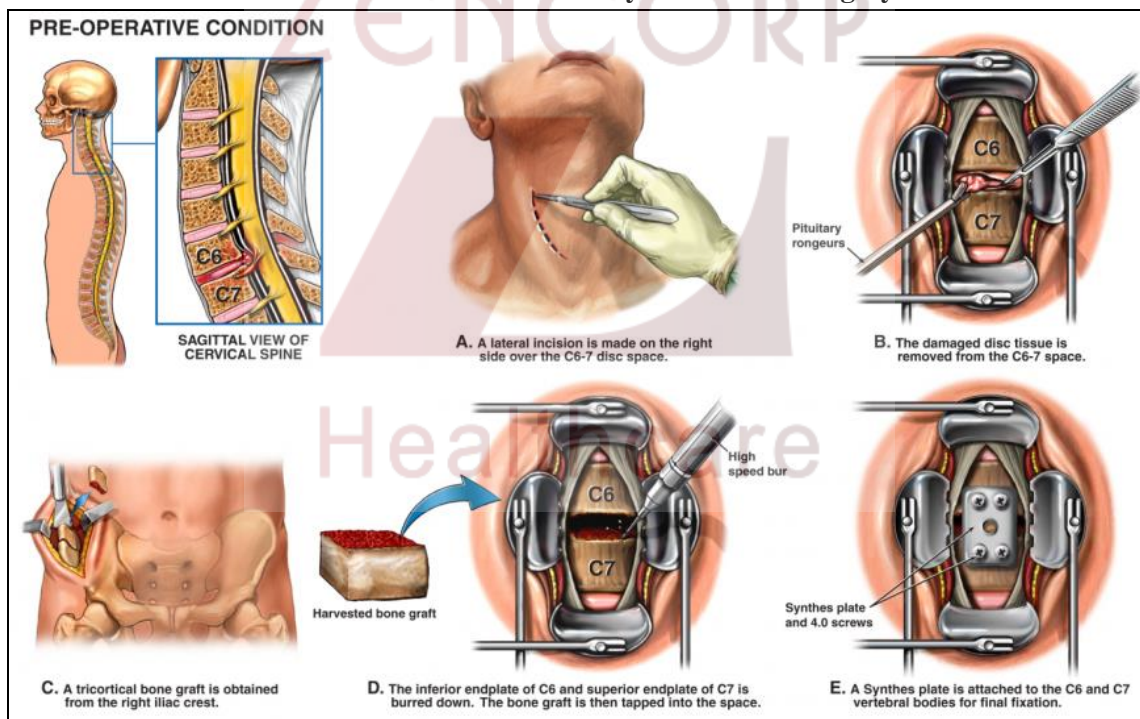
On January 28, 2021, Mr. Doe was seen and evaluated by Stacy C. Brown, PA at Sports Science & Orthopedics (**Exhibit 9**) for complaints of electrical shock-type pain in his neck that radiated down his right arm. He quantified the severity of his pain as 6/10 on the pain scale. A review of his systems was positive for fatigue, neck stiffness, dizziness, speech difficulty, lightheadedness, headaches, easy bruising, nervousness, and anxiety. The findings on his physical examination revealed tenderness in his shoulders. X-ray of his cervical spine that was obtained on December 21, 20xx, revealed disc space narrowing at the C5-C6, C6-C7, and C7-T1 levels. His Physician diagnosed him with cervical neck pain with evidence of disc disease, herniated nucleus pulposus, and cervical radiculopathy. He had failed all conservative treatments, including physical therapy and epidural steroid injections. Therefore, Ms. Brown determined

that he might need to undergo laminectomies and anterior cervical discectomy, and fusion surgery in the future if his symptoms worsened.

Herniated Nucleus Pulposus



Anterior Cervical Discectomy and Fusion Surgery



From October 19, 20xx, through February 1, 2021, Mr. Doe attended his regular chiropractic therapy sessions at The ABC Clinic under the care of Ron Brown, D.C., for the complaints of headaches and pain in his neck, upper back, and low back. On October 19, 20xx, he was recommended to obtain an MRI of his neck and head due to persistent pain and radicular symptoms in his upper extremities, along with severe headaches and continued concussion symptoms. On November 09, 20xx, he complained of headaches and chest pain. His therapist recommended an evaluation with a cardiologist at Heart Hospital South for his chest pain. On November 13, 20xx, he reported persistent pain in his upper back that

radiated into his right arm. He rated the severity of his pain as 9/10 on the pain scale. Given the severe findings on the MRI of his brain and cervical spine, he was recommended to see a neurologist and a spine specialist to evaluate his symptoms further. On December 21, 20xx, he complained of headaches, pain in his low back, and tingling in his hands. On January 11, 2021, he was prescribed Voltaren gel to help manage his pain. He quantified the severity of his pain as 5-7/10 on the pain scale. Despite attending several therapy sessions, his pain had stayed about the same. His treatment consisted of cryotherapy, electrical muscle stimulation, hydrocollator therapy, massage, therapeutic exercises, and ultrasound.

On February 22, 2021, Mr. Doe presented to Steve Randall, M.D., at The ABC Clinic for his final chiropractic evaluation. He complained of intermittent pain and stiffness in his neck, upper back, low back, and SI joints. He had intermittent numbness and tingling in his left upper extremity. He also had constant tightness in his left trapezius. He continued to suffer from headaches approximately three times per week on average. The findings on his physical examination revealed a diminished range of motion and loss of strength in his neck. He had persistent tenderness and trigger points in his neck and entire back muscles. He also had decreased sensation to monofilament testing in his left 2nd through 5th digits and on his right side 1st digit and right lower extremity. He still had palpable spasms and tenderness in his trapezius musculature. He also had palpable tenderness in his sacroiliac joints. His Physician recommended that he undergo a second and third epidural steroid injection to his cervical spine at an approximate cost of \$4,000.00 to \$5,000.00. He also recommended further evaluation with a spine specialist in the future. Dr. Randall determined that he would require an additional physical therapy course at an approximate cost of \$3,000.00 to \$4,000.00 and pain management consultation at an approximate cost of \$2,000.00 to \$3,000.00.

MEDICAL EXPENSES

The medical expenses for the treatment (**Exhibit 10**) of the injuries Mr. Doe suffered because of the collision amounted to **\$23,706.61**. Copies of the medical bills are attached and itemized below:

ABC Hospital	:	\$5,019.25
Medical X-ray Consultants, PLLC	:	\$145.00
The ABC Clinic	:	\$2,085.00
SS Physical Therapy	:	\$3,567.00
Midtown Imaging Services	:	\$3,100.00
Emergency Services of Oklahoma	:	\$1,025.00
Oklahoma Heart Hospital	:	\$2,408.20
MM Diagnostic	:	\$1,150.00
IV Spine Services III	:	\$3,852.00
Gabriel M. Pitman, D.O.	:	\$400.00
Central OK Surgical Services	:	\$850.00
RRS Medical, LLC	:	<u>\$105.16</u>
Total Medical Expenses	:	\$23,706.61

FUTURE MEDICAL EXPENSES

Mr. Doe suffers from pain in his neck, upper back, low back, and trapezius, along with radicular symptoms to his arms and legs, despite undergoing numerous treatments in the form of medications, therapy, and injections. He also has persistent headaches. Therefore, he will need periodic consultations with a pain management and spine specialist to check his pain symptoms. He is prone to develop flare-ups of his symptoms, for which he will require regular consultation with an orthopedist in the future. As per Dr. Randall's recommendation, he will need to receive second and third epidural steroid injections to help alleviate his pain. He will also require additional physical and chiropractic therapy courses to help restore his usual range of motion, strength, and function. As per his physician assistant, Ms. Brown's recommendation, he will require to undergo laminectomies and anterior cervical discectomy and fusion surgery if both therapy and injections fail to provide him enough relief. He will also require additional consultation with a neurologist to address his headaches. He will have to undergo diagnostic imaging from time to time to check his neck, upper back, and low back status. He will require periodic refills of pain medications to help alleviate his pain. The estimates of his medical expenses in the future are as follows:

Spine Consultation	:	\$2,500.00-\$3,000.00
Pain Management Consultation	:	\$2,000.00-\$3,000.00
Orthopedic Consultation	:	\$3,000.00-\$4,000.00
Neurology Consultation	:	\$3,500.00-\$4,000.00
Cervical Epidural Steroid Injections	:	\$8,000.00-\$10,000.00
Laminectomies and		
Anterior Cervical Discectomy and Fusion	:	\$100,000.00-\$120,000.00
Physical Therapy	:	\$3,000.00-\$4,000.00
Chiropractic Therapy	:	\$2,500.00-\$3,000.00
Diagnostic Studies	:	\$2,000.00-\$2,500.00
Medications	:	<u>\$1,000.00-\$1,200.00</u>
Total future medical expenses	:	\$127,500.00-\$154,700.00

IMPACT ON LIFESTYLE

Mr. Doe, a 60-year-old male, had always been peaceful and healthy until August 20xx, when the fateful incident happened. This incident has compelled him to search for a way to address his physical and emotional traumas to move beyond to a more significant recovery. He has adopted numerous lifestyle modifications due to his injuries. Before the collision, he was completely independent with performing his basic daily living activities, and he regularly participated in various activities without any difficulties. However, performing everyday activities, which once felt effortless and straightforward, has become difficult for him. He has difficulty performing even the simplest of activities such as bending, lifting, standing, sitting, twisting, and walking. As such, he finds it highly difficult to perform his household chores and self-care activities. He has numbness and tingling in his right arm, and as a result, he is unable to return to his desired level of activity. He is entirely homebound secondary to his severe pain. He cannot perform his physical activities with the same efficiency as before the collision. He has required more help

than he was accustomed to. His low back pain makes changing positions between sitting and standing extremely difficult for him. His headaches and ringing in his ears have given him a tough time when he tries to concentrate and focus on his everyday tasks. His symptoms affect his logical thinking, decision-making capabilities, and performing specific delicate functions at home. As a result of these limitations, he has diminished self-esteem and self-efficacy. His pain limits him from participating in social gatherings or taking some time to enjoy his life with his family and friends.

He neither participates in recreational activities nor in social events due to awful physical pain and cognitive deficits. He has issues with achieving quality sleep as he cannot find a comfortable position to rest himself. This prevents him from getting a good night's sleep. Lack of sleep makes him feel impatient and irritated the following day. Due to the emotional trauma of his incurring physical injuries from the horrifying accident, he is highly stressed. Psychologically, he is depressed due to his pain and inability to perform his regular activities compared to other people of his age. He is emotionally distressed with the level of difficulty he incurred because of the collision. He is also frustrated due to the amount of stress he must endure with his ongoing medical expenses related to this collision. After the collision, he is compelled to let go of his hobbies and refrain from performing his favorite activities.

He is upset due to the ineffectiveness of numerous medications, therapy sessions, and injections that were prescribed to help him recover from his miseries. Unfortunately, these treatments did not give him the expected recovery, which has made his life an ordeal. Since the collision, Mr. Doe spends much of his time making frequent visits to keep his medical appointments. Due to his persistent symptoms, he will have to continue making regular visits to the hospital. Keeping his regular medical appointments will be exhausting for him, considering his age. His treatments' regularities will not end any time sooner but will continue even further into the future, in the form of physical and chiropractic therapy sessions, injections, regular follow-ups, and even surgery. These additional treatment modalities will still put him under a great deal of financial and psychological stress. He yearns to return to his pre-injury state, which is difficult to the extent of not seeing any improvement in his physical and social well-being, even in the future.

Mr. Doe's lifestyle has completely changed, and he is no longer active and enthusiastic. He is forced to lead a restricted life due to his pain. Based on the nature of the injuries he sustained from the collision, it is evident that Mr. Doe will continue to suffer from debilitating pain and lifelong impairments, despite receiving extensive medical care, for which he must be justly compensated. Damages for his pain and suffering, loss of activities, and impact on his life are in the sum of \$_____.

SUMMARY OF DAMAGES

Under state law, a plaintiff can recover the following damages in a negligence action: (a) physical pain and suffering, past and future; (b) mental pain and suffering, past and future; (c) age; (d) physical condition immediately before and after the accident; (e) the nature and extent of injuries; (f) whether the injuries are permanent; (g) the physical impairment; (h) disfigurement; (i) loss of earnings and/or time; (j) impairment of earning capacity; and (k) the reasonable expenses of the necessary medical care, treatment, and services, past and future.

A brief summary of Johnny Doe's damages is provided below:

Medical Expenses	:	\$23,706.61
Future Medical Expenses	:	\$127,500.00-\$154,700.00
Lifestyle Impact/Loss of Activities	:	

CONCLUSION

Demand is hereby made before the sum of \$_____. Should you have any questions, please do not hesitate to contact our office. Johnny Doe will be responsible for any and all liens.

Yours very truly,





ZENCORP

TABLE OF CONTENTS



Healthcare

TABLE OF EXHIBITS

Exhibit 1	:	Oklahoma Highway Patrol
Exhibit 2	:	ABC Hospital
Exhibit 3	:	The ABC Clinic
Exhibit 4	:	SS Physical Therapy
Exhibit 5	:	ABC Diagnostic Imaging
Exhibit 6	:	Heart Hospital South
Exhibit 7	:	MM Diagnostic
Exhibit 8	:	IV Spine Services
Exhibit 9	:	Sports Science & Orthopedics
Exhibit 10	:	Medical Expenses

Healthcare